

Bilateral Total Hip Arthroplasty Comparing Hydroxyapatite Coating to Porous-Coated Fixation

Lawrence D. Dorr, MD, Zhinian Wan, MD, Michael Song, BA,
and Anil Ranawat, BS

Abstract: Fifteen patients had bilateral hip replacement with a porous-coated hip replacement in one hip and in the contralateral hip the same design, which had adjunctive hydroxyapatite coating on the porous coating. These patients were followed for an average of 6.5 years (range, 5–7.9 years). There was no difference in the clinical Harris Hip Scores between the two hips in these patients. The radiographic measurements did show improved bone remodeling in hips with adjunctive hydroxyapatite coating as measured by proximal cancellous hypertrophy and evidence of a buttress sign. The fixation of stems with hydroxyapatite coating showed fewer radiolucent lines ($P = .013$). The improved bone remodeling, which we had previously reported, has been maintained in these hips at intermediate-term follow-up and the fixation of the hydroxyapatite-coated stems is also now better. The results in these patients with bilateral hips, which allows complete control of the bone type, immunology, weight, activity, and age of the patient, suggests that the use of hydroxyapatite coating does provide improved fixation and the possibility of improved durability. **Key words:** hydroxyapatite, bilateral total hip arthroplasty, noncemented stem, fixation of stem.

Within the controversy about the advantages of bone ingrowth total hip arthroplasty stems is a separate concern about the efficacy of hydroxyapatite as a fixation surface material [1–9]. Does hydroxyapatite promote earlier fixation of the stem and by doing so enhance fixation? Will earlier fixation result in a more stable and durable clinical outcome?

Several reports have shown satisfactory early clinical results with hydroxyapatite-coated hip prostheses. Clinical series by both Geesink et al. [10,11] and D'Antonio et al. [12] have reported excellent

clinical and radiographic results with the Omnifit stem (Osteonics, Allendale, NJ), which has proximal hydroxyapatite coating on a textured surface. A matched-pair comparison of proximal hydroxyapatite on plasma-spray surface stems (Taperloc, Biomet, Warsaw, IN) versus plasma-spray surface alone has better clinical results in the first 6 months with hydroxyapatite but no other clinical or radiographic differences at 2 years after surgery [13]. McPherson et al. [14] found better bone remodeling but no clinical differences in a 3-year matched-pair comparison of hydroxyapatite on a proximal patched porous-coated stem versus porous-coated-only stem (Anatomic Porous Replacement, APR-I, Intermedics Orthopedics, Austin, TX). Hydroxyapatite coating has been found to reduce subsidence of the femoral stem compared to both porous-coated-only and cemented stems at 1 and 2 years after surgery [15,16]. These short-term studies have shown that increased

From the University of Southern California, Center for Arthritis and Joint Implant Surgery, USC University Hospital, Los Angeles, California.

Reprint requests: Lawrence D. Dorr, MD, USC Center for Arthritis and Joint Implant Surgery, USC University Hospital, 1450 San Pablo Street, 5th Floor, Los Angeles, CA 90033.

Copyright © 1998 by Churchill Livingstone®
0883-5403/1307-0001\$3.00/0

early bone remodeling and stability may or may not be correlated with better clinical hip scores, but there has been no evidence that these findings mean prolonged better fixation.

Many factors affect both the clinical and radiographic results after total hip arthroplasty. The use of matched-pair studies is an accepted means of comparing results between two groups of patients. Even more reliable is the use of a randomized study for comparison. Another method of comparing prosthetic design differences is the use of these implants in the same patient in opposite hips. We used this method of comparison of the same hip replacement design in patients who have bilateral hip replacement with one of the hips having the addition of hydroxyapatite coating to the porous-coated stem, which was implanted. The purpose of this study was to determine if there is a difference between the response to two different types of fixation within the same patient at 5 years or more after surgery.

Materials and Methods

From 1988 to 1991, there were 96 hips that had hydroxyapatite coating plasma-sprayed onto porous coating implanted by one of us (L.D.D.). In 15 patients with 30 bilateral primary total hip arthroplasties, one hip was implanted with a proximal porous-coated femoral stem and the contralateral hip with a stem that had hydroxyapatite plasma sprayed onto the porous coating. Nine patients had both hips replaced at the same operation; in four patients the hydroxyapatite hip was implanted first with 3, 8, 10, and 21 months' difference; in two patients the porous hip was implanted first with 3 and 22 months' difference. An anatomic porous replacement-I hip stem (APR I, Intermedics Orthopedics, Austin, TX) was implanted in 9 patients (18 hips) and 6 patients (12 hips) had an anatomic porous replacement-II femoral stem (APR-II, Intermedics Orthopedics) (Fig. 1). The femoral component size was identical in 12 patients, and in 3 patients the hydroxyapatite-coated stems were one size larger (sometimes one hip has more disuse osteoporosis than the other). The neck length used was equal in six patients, longer in the hydroxyapatite hip in three, and longer in six porous hips (the neck length can vary by depth of acetabular reaming). In the 12 hips with anatomic porous replacement-II stems, 11 had a diaphyseal sleeve. All acetabular components were those of the anatomic porous replacement hip system (Fig. 1).

The anatomic porous replacement-I hip stem was made of titanium alloy and had cancellous-structured patched porous coating placed on the proxi-



Fig. 1. The stem on the right side of this figure is the anatomic porous replacement-I with patched porous coating. On the left is the anatomic porous replacement-II which has no porous coating on the lateral side of the stem.

mal 20 to 30 mm according to implant size. The porous surfaces were applied by a heat sintering process. There was a porous-coated collar and a posterior bow of 10°. The porous coating had pores that averaged 450 μm and volume of porosity that averaged 55%. The pore size was increased to 750 μm on the hydroxyapatite-coated stems to accommodate the partial closure of pores that occurs when hydroxyapatite is plasma-sprayed onto the porous coating. The average pore size after application of the hydroxyapatite coating was $490 \pm 30 \mu\text{m}$. The average thickness of the hydroxyapatite coating was $55 \pm 5 \mu\text{m}$. The hydroxyapatite porous coating used has been analyzed chemically by the manufacturer (Intermedics Orthopedics) and is 94% pure hydroxyapatite, with crystallinity of 72% and specific gravity of 3.02 with a calcium:phosphate ratio of 1.75:1. Materials tested by the manufacturer showed that the hydroxyapatite bond to titanium alloy substrate had a shear strength of 34 to 48 MPa and a tensile strength of 45 to 48 MPa.

The anatomic porous replacement-II femoral component used the same hydroxyapatite and application method for the hydroxyapatite to the porous coating. The anatomic porous replacement-II implant did not have patched porous coating but had a continuous porous coating over the same area of the prosthesis on the medial, anterior, and posterior surfaces but not on the lateral surface (not circum-

ferential). The anatomic porous replacement-II geometry was lengthened by 25 mm from that of the anatomic porous replacement-I stem length and had a round stem rather than a rectangular stem. The posterior bow with the anatomic porous replacement-II geometry is 12° compared to 10° with the anatomic porous replacement-I geometry. With the anatomic porous replacement-II the pore size was not increased before application of the hydroxyapatite. The pore size of the anatomic porous replacement-II had been increased to $558.8 \pm 34.8 \mu\text{m}$ with a pore volume of $56.5 \pm 4.3\%$. With the plasma-spray application of the hydroxyapatite the pore size is reduced to $442.9 \pm 16.5 \mu\text{m}$ with a pore volume of $41.9 \pm 4.1\%$.

The acetabular components for the porous control hips were fully porous-coated except for a 1-cm area on the central dome. The hydroxyapatite porous acetabular components were identical with the addition of hydroxyapatite coating applied without a prior increase in pore size. These acetabular components were titanium-aluminum-vanadium alloy and were hemispheric in shape with 3-mm thick walls. There was a cluster hole pattern of screw holes that varied in number from 7 to 9 according to the size of the acetabular component.

Clinical and radiographic data were collected before surgery, at 3, 6, and 12 months, and yearly thereafter. The level of pain, as well as functional parameters such as the walking distance, stair climbing, need for external support, sitting ability, limp, range of motion, and participation in recreational activities were evaluated at each visit, providing a composite Harris Hip Score [6].

Anteroposterior view radiographs of the pelvis and Lowenstein lateral view radiographs of the hip were made before surgery and at each postoperative visit. Correction for magnification was calculated for each radiograph by the ratio of the measured diameter of the prosthetic head to the actual known diameter. The preoperative radiographs were evaluated for the type of bone [17] and for the calcar: canal ratio and the cortical index [18]. The percentage of the canal filled by the femoral component at four levels was measured on anteroposterior view radiographs. These levels are named calcar fill, metaphyseal fill, midstem, and distal fill [19]. Stem bone ratio was also measured from the anteroposterior view radiographs of the pelvis. Lateral distal fill was the only measurement obtained from the lateral view radiograph [19].

Fixation was graded by the presence of radiolucent lines and migration of the stem. Radiolucent lines were measured by zones on radiographs showing both anteroposterior and lateral views [20]. A

total of 14 zones were measured with 7 on the anteroposterior view and 7 on the lateral view radiographs. A radiolucent line must encompass at least 50% of the length of the zone to be recorded. Subsidence of the stem was measured by using the apex of the lesser trochanter as a reference point.

Bone remodeling was categorized as calcar resorption, distal cortical hypertrophy, and formation of a proximal spot weld called the "buttress sign" [14]. Cancellous hypertrophy was defined as new bone formation between the implant and endosteal surface of the bone and is the bone remodeling change that occurs with the buttress sign (Fig. 2). The comparison used for bone remodeling is made between the bone on the 6-week postoperative radiographs compared with the 2-year and last follow-up radiographs. Calcar resorption [21] and distal cortical hypertrophy [22] were recorded. Heterotopic bone formation was recorded according to the classification of Brooker et al. [23]. Focal osteolysis [24] was measured by zones.

Migration of the acetabular component was defined as linear (direction of medial, superior, or both) or rotational (change in theta angle). Migration was determined by comparing sequential films

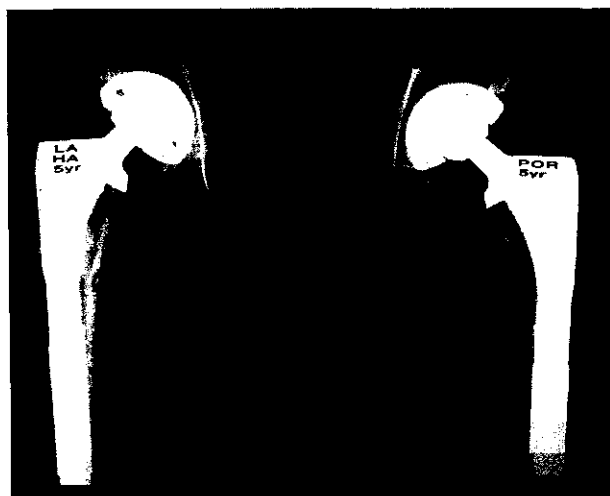


Fig. 2. Radiograph of bilateral total hip arthroplasties 5 years after surgery. The right hip has a hydroxyapatite-coated stem which shows cancellous hypertrophy both medially and laterally at the base of the porous coating (buttress sign). The left hip is a porous-coated-only stem with no evidence of the buttress sign. At the junctional corner of the collar and the medial porous coating is smooth metal (between the porous coating on the collar and the medial porous coating). At this junctional corner in both hips can be seen an area of bone loss from stress shielding by failure of the bone to attach to the smooth metal.

and measuring the distance between the acetabular component and both Kohler's line and the tear-drop [25]. The angle of inclination of the cup was measured by the method described by Callaghan et al. [26]. Polyethylene wear was measured by comparing the postoperative radiograph with that taken at final follow-up [25]. Analysis of the radiolucent lines and osteolysis about the acetabulum was performed using the three zones described by DeLee and Charnley [27]. One patient had a 28-mm femoral head in the porous-coated hip and a 26-mm head in the hydroxyapatite-coated hip. The other 14 patients with bilateral hips had the same head size in each hip with 26-mm heads used in three patients, 28 mm in six patients, and 32 mm in five patients.

SPSS statistical software was used to analyze the data (SPSS Inc, Chicago, IL). Clinical and radiographic results were statistically compared between the hydroxyapatite-coated and porous-coated hips. Student's *t* test was employed for the calcar canal ratio, cortical index, stem:bone ratio, calcar fill, metaphyseal fill, anteroposterior midstem fill, anteroposterior distal fill, lateral view radiographic distal fill, acetabular component angle, and polyethylene wear. The chi-square test was used for statistical comparison of clinical results, Dorr bone types, bone remodeling, radiolucent lines, and osteolysis.

Results

The demographics for the patients are the same for each comparison because each patient acts as his or her own control. The average age at operation was 55 years (range, 38–71 years); 5 patients were women and 10 patients were men. Bilateral hips of the patients had the same diagnosis before surgery, with osteoarthritis in 10 patients, avascular necrosis in 4, and rheumatoid arthritis in 1. The average follow-up was 6.5 years (range, 5–7.9).

The clinical scores at follow-up, including the pain score, limp score, and total Harris Hip Score, were not significantly better in the hydroxyapatite-coated hips. The pain score averaged 40.1 in the hydroxyapatite hips and 41.7 in the porous-coated only hips ($P = .48$); the limp score averaged 10.1 versus 10.8 ($P = .65$); the total Harris Hip Score averaged 93.5 versus 95.5 ($P = .45$).

Bone parameters, including bone type and measurements of stem fill in the bone, did not differ (Table 1). Likewise, acetabular component theta angles and anteversion were not statistically different (Table 1).

Bone remodeling measurements revealed medial metaphyseal cancellous bone hypertrophy in 12

Table 1. Comparison of Parameters

Parameter	Hydroxyapatite	Porous	P Value
Dorr bone type (hips)			
A	5	5	1
B	10	10	
C	0	0	
CC ratio	0.57	0.6	.31
C index	0.55	0.53	.38
Stem bone ratio	0.55	0.55	.87
Calcar fill (%)	100	100.9	.76
Metaphyseal fill (%)	95.6	95.3	.9
Midstem (%)	85.8	86.7	.84
Distal fill (%)	96.6	97.6	.54
Lateral distal fill (%)	90.5	89.1	.72
Cup angle (degrees)	47.7	45.1	.23
Polyethylene wear (mm)	0.13	0.14	.75

hips with hydroxyapatite-coated stems and four hips with porous-coated only stems. This increased medial density was present by 1 year and continued to increase in area and density until last follow-up (Fig. 3A, B). Both medial and lateral cancellous hypertrophy at the distal end of the coated surface (buttress sign) was seen in nine hips with hydroxyapatite porous coating and no others ($P = .001$). Atrophy of bone at the junction of the collar and stem occurred in eight hips with hydroxyapatite stems and eight with porous-only stems (Fig. 3A, B). This is expected because at this junctional corner of the stem there is no coating (smooth metal). Distal cortical hypertrophy was present in four hydroxyapatite-coated hips and four porous-coated-only hips. Three hips with hydroxyapatite-coated stems had Brooker grade I, and two had grade II heterotopic bone; three hips with porous-coated stems had grade I and one grade II. No hip had grade III or IV Brooker heterotopic bone.

Osteolysis was observed around three femoral stems in the hydroxyapatite-coated group and five in the porous-coated group. All these hips had osteolysis in the proximal femur in zones 1 and 7. Distal osteolysis also occurred in one hydroxyapatite hip and three porous-only hips (Fig. 4). There was no difference between the hips in the overall incidence of osteolysis of the femur ($P = .41$).

Measurement of fixation in the proximal zones (zones 1, 2, 6, 7, 8, 9, 13, 14) showed fewer radiolucent lines and stems with hydroxyapatite porous coating ($P = .013$) (Table 2; Fig. 4). The porous coating on the stem extends partially into zones 2, 6, 9, and 13. There was no statistical difference in the occurrence of radiolucent lines between the stems for zones 3, 4, 5, 10, 11, and 12. No stem in either group had measurable migration.

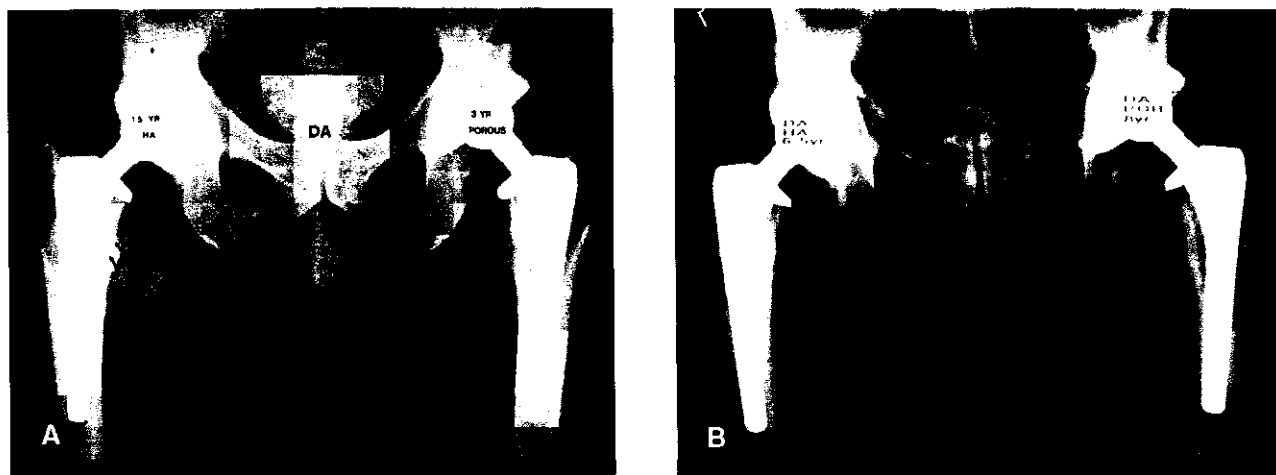


Fig. 3. (A) Radiograph of bilateral total hip arthroplasties. The right hip has a hydroxyapatite-coated stem, which shows dense medial cancellous hypertrophy in zone 7 at 1.5 years. The left hip is porous-coated-only stem without medial or lateral cancellous hypertrophy. (B) Same hips 5 years later, which show extension of medial endosteal bone remodeling into zone 6. There is development of a pedestal at the tip of the left hip, which is the porous-only stem.

Socket fixation revealed no radiolucent line around any acetabular component in either type of hip. One patient had osteolysis in zone 1 of both acetabulae and also proximal osteolysis adjacent to the hydroxyapatite-coated stem. She was reoperated for exchange of the polyethylene and femoral head of both hips, and all components were stable

and not revised. No acetabulum was radiographically loose and none was revised.

Measurement of polyethylene wear in these hips is confounded by the 0.5- to 0.75-mm gap between the polyethylene insert and the metal component. In the first 3 months postoperative the gap closes by loading of the hip [19]. In these hips, after correcting for this immediate creep of the polyethylene, the average linear wear in hydroxyapatite-coated and porous-coated hips with 26-mm heads was 0.14 mm per year; in porous-coated hips with 28-mm heads was 0.14 mm per year, in hydroxyapatite-coated hips was 0.11 mm per year; and in porous-coated hips with 32-mm heads was 0.134 versus 0.139 mm per year in HA hips. Overall, the average yearly linear wear in porous hips was 0.14 mm and in hydroxyapatite-coated hips was 0.13 mm.

Discussion

The use of comparison of results of arthroplasty surgery by using bilateral operations in the same patient has been previously reported. Wiesman et



Fig. 4. Radiographs of bilateral total hip arthroplasties 7 years after surgery. The right hip is a hydroxyapatite-coated stem, which has osteolysis under the collar. The left hip is a porous-coated only stem, which has osteolysis in all zones around the stem. There is significant wear with both hips which is equal.

Table 2. Comparison of Radiolucent Lines

	Hydroxyapatite Coating	Porous Coating	P Value
All zones	4.1	7.8	.026
Zones 1, 2, 6, 7	1.3	3.6	.013
Zones 3, 4, 5	2.7	4.2	.1

al. [28] compared the results of total hip arthroplasty in 12 patients with one hip having trochanteric osteotomy and one a posterior approach. Dorr et al. [29] compared posterior cruciate-sacrificing versus saved total knee replacements implanted in opposite knees in 12 patients using gait analysis. The advantage of this method of comparison is that the activity level, weight, age, bone metabolism, emotional response, and immunology are absolutely controlled. Probably no other comparative method is as accurate in comparing muscle response and bone response with an arthroplasty.

We reported that at an average 3-year follow-up in matched-pair analysis there was no difference in the clinical results between porous-coated stems and hydroxyapatite porous-coated stems [14]. There was a difference in bone remodeling between these two groups at all time periods evaluated during this 3-year follow-up. Rothman et al. [13] confirmed these clinical findings in a matched-pair study of 52 pairs of patients. No clinical or radiographic differences were observed. However, this same group of investigators did report improved clinical results with hydroxyapatite-augmented plasma-sprayed hip stems at 3 and 6 months in a randomized study using the Taperloc prosthesis (Biomet, Warsaw, IN). Karrholm et al. [30] had no clinical differences with proximal hydroxyapatite porous-coated stems compared with a plain porous-coated stem and a third group with a cemented stem.

The best prosthetic stability has been demonstrated with proximal hydroxyapatite-augmented stems, which also had a diaphyseal grit-blasted surface. Karrholm et al. [30] used stereophotogrammetric analysis to demonstrate less motion during the first 2 years postoperative when compared with the same stem with porous-coated-only proximal surface finish (TIFIT, Smith and Nephew Richards, Memphis, TN) and a cemented stem in a third group. In a second study in which a hydroxyapatite-coated stem was compared with a cemented stem, no difference in subsidence was measured during the first 2 years after surgery [31]. This study utilized a specially designed prosthesis to measure radiographic vertical migration using a digitizing tablet (Orthographics Inc., Salt Lake City, UT). A third study using stereophotogrammetric analysis compared proximal plasma spray-coated stems with one having proximal hydroxyapatite added [16]. The results of this study again showed the hydroxyapatite stem stabilized at 3 months, and those hips also had better clinical results at 2 years. Only the study by Ciccotti et al. [32] had no difference by stereophotogrammetric analysis between the proxi-

mal hydroxyapatite-coated Taperloc and the stem without hydroxyapatite.

Autopsy implant material is one accepted method for evaluating well-functioning arthroplasties. An autopsy implant retrieval analysis of bilateral hips from a patient with an anatomic porous replacement-I hip porous-coated stem and contralateral hydroxyapatite-augmented stem showed more bone attachment to the hydroxyapatite porous-coated stem [33]. A second autopsy retrieval at 3 weeks after surgery, reported from the same laboratory, showed osteoid on 20% of the hydroxyapatite surface and new bone on 10% at this early time period [34]. Lintner et al. [35] studied an autopsy retrieval 10 months after surgery, which showed extensive new bone formation between the hydroxyapatite coating and host bone but also the presence of resorption lacunae on the hydroxyapatite coating. Bauer et al. [1] have also observed resorption lacunae in stems with predominantly bone-hydroxyapatite coating attachment.

These biomechanical and autopsy retrieval studies support the bioconductive capability of adjunctive hydroxyapatite coating on porous coating to provide earlier stability of the stem and more bone attachment to the prosthesis. The finding by two investigators that proximal coated hydroxyapatite with distal grit-blasted stems have less subsidence or migration than cemented stems is impressive [30,31]. These findings explain the earlier appearance and more frequent finding of a buttress formation at the base of the fixation surface. Geesink [10] reported 87% and D'Antonio et al. [12] 88% of hips with the hydroxyapatite Omnifit stem had a buttress sign at 6 years postoperative. Soballe et al. [16] at 2 years had 84% with buttress sign remodeling with hydroxyapatite-augmented stem and 33% in titanium plasma-sprayed-only Biometric stems. McPherson et al. [14], using the patched porous-coated anatomic porous replacement-I, observed more cancellous hypertrophy in the hydroxyapatite hips at all follow-up periods to 3 years postoperative. At 3 years after surgery, 81% of hips with hydroxyapatite porous coating had buttress sign remodeling, and 55% of porous-coated hips had medial-only cancellous hypertrophy. In this current study of bilateral hips, nine hydroxyapatite stems had a buttress sign, while none of the hips with porous-coated-only stems did. In both the study of McPherson et al. [14] and in our study, the type and incidence of bone remodeling was not correlated to bone type or bone measurements. Therefore, the bone remodeling differences can only be attributed to the difference of the adjunctive hydroxyapatite fixation surface.

Our study shows that early radiographic evidence of endosteal bone formation appears to translate into better fixation with the stems studied. Therefore, the worse fixation grade in the hips in this study with porous-coated only stems is predictive of earlier loosening and failure. In anatomic porous replacement-II hips with hydroxyapatite coating, the occlusion of pores with plasma-sprayed hydroxyapatite did not change the improved radiographic fixation. This finding, in concert with the results with the Omnifit stem with only a textured surface, suggests that hydroxyapatite needs only a roughened surface to function well.

In our study, clinical results did not differ even with better fixation, most likely because in this study the patient is his or her own control. Pain scores did not differ because none of the implants are yet loose. The only patient with a painful hip and revised stem was one with a hydroxyapatite-coated stem. This patient's painful hip was not resolved with a cemented revision stem and was ultimately resolved only after spinal surgery.

The overall wear in these hips was high with an average of 0.136 mm per year of linear wear. The reason for this wear rate is because of the liner fit into the acetabular shell and has been discussed in previous publications. Wear and osteolysis was not increased in hips that had hydroxyapatite porous-coated stems. This finding is important because Bloebaum et al. [36,37] had anticipated this might be the case, based on experience with implant retrievals obtained at revisions. Buma and Gardiniers [38] expressed similar concerns of fragmentation and loss of hydroxyapatite coating, as observed from a single stem revised for thigh pain. D'Antonio et al. [12] and Geesink [10] have not observed osteolysis with the hydroxyapatite Omnifit stem. Bauer et al. [1] and Lintner et al. [35] have not observed fragmentation in implant retrievals. Hydroxyapatite resorption and, probably, fragmentation most likely do occur but do not seem to promote increased wear and osteolysis in the absence of loose implants.

Moilanen et al. [39] confirmed our results of no increased wear with the use of hydroxyapatite-coated implants. Their study on acetabular components also agreed with our findings that the fixation of these sockets reveals few radiolucent lines. In their study migration was less with the hydroxyapatite-coated components than press-fit-only acetabular components.

Adjunctive hydroxyapatite coating on these stems is predictive of better fixation in the first 7 years. The hip stems used in this study are no longer available clinically. The failure rate of the anatomic porous

replacement-I was unacceptably high [19]. Therefore, the success of the addition of hydroxyapatite to the porous coating of these hip stems in these bilateral arthroplasties accentuates the usefulness of this bioconductive material. We still use the anatomic porous replacement-II geometry with circumferential proximal porous coating and grit-blasted diaphyseal stems in all patients. We use this stem with adjunctive hydroxyapatite proximal coating in patients 60 years of age and younger.

References

1. Bauer TW, Geesink RCT, Zimmerman R, McMahon JT: Hydroxyapatite-coated femoral stems: histological analysis of components retrieved at autopsy. *J Bone Joint Surg [Am]* 73:1439, 1991
2. Collier JP, Surprenant VA, Mayor MB, Wrona M, Jensen RE, Surprenant HP: Loss of hydroxyapatite coating on retrieved, total hip components. *J Arthroplasty* 8:389, 1993
3. Furlong RJ, Osborn JF: Fixation of hip prostheses by hydroxyapatite ceramic coatings. *J Bone Joint Surg [Br]* 73:741, 1991
4. Geesink RGT, de Groot K, Klein CPAT: Chemical implant fixation using hydroxyl-apatite coatings: the development of a human total hip prosthesis for chemical fixation to bone using hydroxyapatite coatings on titanium substrates. *Clin Orthop* 225:147, 1987
5. Geesink RGT, de Groot K, Klein CPAT: Bonding of bone to apatite-coated implants. *J Bone Joint Surg [Br]* 70:17, 1988
6. Harris WH: Traumatic arthritis of hip after dislocation and acetabular fractures—treatment by mold arthroplasty: an end result study using a new method of result evaluation. *J Bone Joint Surg [Am]* 51:737, 1969
7. Soballe K, Hansen ES, Brockstedt-Rasmussen H, Pedersen CM, Bunger C: Hydroxyapatite coating enhances fixation of porous coated implants: a comparison in dogs between press fit and noninterference fit. *Acta Orthop Scand* 61:299, 1990
8. Soballe S, Hansen ES, Rasmussen HB, Bunger C: Hydroxyapatite coating converts fibrous tissue to bone around loaded implants. *J Bone Joint Surg [Br]* 75:270, 1993
9. Thomas KA, Cook SD, Haddad RJ, Kay JF, Jarcho M: Biologic response to hydroxyapatite-coated titanium hips: a preliminary study in dogs. *J Arthroplasty* 4:43, 1989
10. Geesink RGT: Hydroxyapatite-coated total hip prostheses: 2 years clinical and roentgenographic results of 100 cases. *Clin Orthop* 261:39, 1990
11. Geesink RGT, Hoefnagels NHM: Six-year results of hydroxyapatite-coated total hip replacement. *J Bone Joint Surg [Br]* 77:534, 1995
12. D'Antonio JA, Capello WN, Jaffe WL: Hydroxyapatite-coated hip implants: multicenter three-year clinical

- and roentgenographic results. *Clin Orthop* 285:102, 1992
13. Rothman RH, Hozack WJ, Ranawat A, Moriarty L: Hydroxyapatite-coated femoral stems: a matched pair analysis of coated and uncoated implants. *J Bone Joint Surg [Am]* 78:319, 1996
 14. McPherson EJ, Dorr LD, Gruen TA, Saberi MT: Hydroxyapatite-coated proximal ingrowth femoral stems: a matched pair control study. *Clin Orthop* 315:223, 1995
 15. Kroon PO, Freeman MAR: Hydroxyapatite coating on hip prostheses: effect on migration into the femur. *J Bone Joint Surg [Br]* 74:518, 1992
 16. Soballe K, Toksvik-Larsen S, Gelineck J et al: Migration of titanium alloy and hydroxyapatite coated femoral components in total hip arthroplasty. *Acta Orthop Scand* 63:34, 1992
 17. Dorr LD, Faugere MC, Mackel AM, Gruen TA, Bognar B, Malluche HH: Structural and cellular assessment of bone quality of proximal femur. *Bone* 14:231, 1993
 18. Dorr LD, Abzatz M, Gruen TA, Saberi MT, Doerzbacher JF: Anatomic porous replacement hip arthroplasty: first 100 consecutive cases. *Semin Arthroplasty* 1:77, 1990
 19. Dorr LD, Lewonowski K, Lucero M, Harris M, Wan Z: Failure mechanisms of APR-I cementless total hip replacement. *Clin Orthop* 334:157, 1997
 20. Gruen TA, McNeice GM, Amstutz HC: Modes of failure of cemented stem type femoral components: a radiographic analysis of loosening. *Clin Orthop* 141:17, 1979
 21. Capello WN, Sallay PI, Feinberg JR: Omniflex modular femoral component: two- to five-year results. *Clin Orthop* 298:54, 1994
 22. D'Antonio JA, Capello WN, Manley MT: Remodeling of bone around hydroxyapatite-coated femoral stems. *J Bone Joint Surg [Am]* 78:1226, 1996
 23. Brooker AF, Bowerman JW, Robinson RA, Riley LH Jr: Ectopic ossification following total hip replacement: incidence and a method of classification. *J Bone Joint Surg [Am]* 55:1629, 1973
 24. Wan Z, Dorr LD: Natural history of femoral focal osteolysis with proximal ingrowth smooth stem implant. *J Arthroplasty* 6:718, 1996
 25. Dorr LD, Wan Z: Ten years of experience with porous acetabular components for revision surgery. *Clin Orthop* 319:191, 1995
 26. Callaghan JJ, Salvati EA, Pellicci PM, Wilson PD Jr, Ranawat CS: Results of revision for mechanical failure after cemented total hip replacement, 1979 to 1982: a two to five year follow-up. *J Bone Joint Surg [Am]* 67:1074, 1985
 27. DeLee JG, Charnley J: Radiological demarcation of cemented sockets in total hip replacement. *Clin Orthop* 121:20, 1976
 28. Wiesman HJ Jr, Simon SR, Ewald FC, Thomas WH, Sledge CB: Total hip replacement with and without osteotomy of the greater trochanter: clinical and biomechanical comparisons in the same patients. *J Bone Joint Surg [Am]* 60:203, 1978
 29. Dorr LD, Ochsner JL, Gronley J, Perry J: Functional comparison of posterior cruciate-retained versus cruciate-sacrificed total knee arthroplasty. *Clin Orthop* 236:36, 1988
 30. Karrholm J, Malchau H, Snorrason F, Herberts P: Micromotion of femoral stems in total hip arthroplasty: a randomized study of cemented hydroxyapatite-coated, and porous-coated stems with roentgenstereophotogrammetric analysis. *J Bone Joint Surg [Am]* 76:1692, 1996
 31. Freeman MAR, Plante-Bordebeuve P: Early migration and late failure of proximal femoral prostheses. *J Bone Joint Surg [Br]* 76:432, 1994
 32. Ciccotti MG, Rothman RH, Hozack WJ, Moriarty L: Clinical and roentgenographic evaluation of hydroxyapatite-augmented and nonaugmented porous total hip arthroplasty. *J Arthroplasty* 9:631, 1994
 33. Bloebaum RD, Bachus KN, Rubman MH, Dorr LD: Postmortem comparative analysis of titanium and hydroxyapatite porous-coated femoral implants retrieved from the same patient: a case study. *J Arthroplasty* 8:203, 1993
 34. Bloebaum RD, Merrell M, Gustke K, Simons M: Retrieval analysis of a hydroxyapatite-coated hip prosthesis. *Clin Orthop* 267:97, 1991
 35. Lintner F, Bohm G, Huber M, Scholz R: Histology of tissue adjacent to an HAC-coated femoral prosthesis: a case report. *J Bone Joint Surg [Br]* 76:824, 1994
 36. Bloebaum RD, Dupont JA: Osteolysis from a press-fit hydroxyapatite-coated implant: a case study. *J Arthroplasty* 8:167, 1993
 37. Bloebaum RD, Beeks D, Dorr LD, Savory CG, DuPont JA, Hofmann AA: Complications with hydroxyapatite-coated particulate separation in total hip arthroplasty. *Clin Orthop* 298:19, 1994
 38. Buma P, Gardeniers JWM: Tissue reactions around a hydroxyapatite-coated hip prosthesis: case report of a retrieved specimen. *J Arthroplasty* 10:389, 1995
 39. Moilanen T, Stocks GW, Freeman MAR, Scott G, Goodier WD, Evans SJW: Hydroxyapatite coating of an acetabular prosthesis: effect on stability. *J Bone Joint Surg [Br]* 78:200, 1996