

Painful Metal-on-Metal Total Hip Arthroplasty

Cambize Shahrदार, MD,* Pat Campbell, PhD,†
Joseph Mirra, MD,† and Lawrence D. Dorr, MD*

Abstract: Two patients were evaluated for the possibility of hypersensitivity to a Metasul articulation (Centerpulse, Austin, Tex) coupled with total hip arthroplasty. Serum was tested with a lymphocyte proliferation assay, and the capsular tissues from the hip were examined for perivascular lymphocytes. The diagnosis of hypersensitivity to Metasul could not be confirmed in these patients, and ultimately, the painful hip arthroplasties were felt to be caused by a combination of musculoskeletal problems. **Key words:** metasul, hypersensitivity, metal allergy, revision, painful total hip arthroplasty.
© 2006 Elsevier Inc. All rights reserved.

The possibility of metal-on-metal total hip arthroplasty producing a delayed-type hypersensitivity reaction to the chromium or cobalt ions has been examined by Willert et al [1,2]. He found the periprosthetic tissue in retrieved tissue samples from early metal-on-metal total hip arthroplasties to contain macrophages with metallic particles in them. These macrophages were consistently found in areas in the direct vicinity of blood vessels (mostly in the capsule), as well as granulomas with metal particles in the tissues [2]. He has also described the histopathologic changes in the soft tissue surrounding the newer metal-on-metal total hip articulations as having significantly less wear particles and less granulomas but having the presence of perivascular lymphocytic infiltrates

characteristic of cell-mediated immune response (delayed-type hypersensitivity reaction) [1].

The literature does not have any documented cases of patients operated specifically because of the diagnosis of hypersensitivity to the metal and the clinical response to the revision operation. The senior author (LDD) has performed 2 revisions for possible hypersensitivity to chromium or cobalt of Metasul articulations. Our purpose was to describe the case reports of these 2 patients.

Case 1

A 60-year-old man had a right total hip arthroplasty with a noncemented Anatomic Porous Replacement stem and a Converge cup with Metasul articulation (Centerpulse, Austin, Tex). He never gained good pain relief or functional recovery with that right total hip arthroplasty. At 6 months after surgery, the patient complained of groin pain that radiated to his right knee. This pain was worst with start-up activities and did persist with ambulation, and he limped. He was taking narcotic medication at night. On physical examination, he had strong muscles. His range of motion was 30° of abduction, 30° of external rotation, and 100° of flexion without contractures. The radiographs showed that he had good fixation of the

*From the *Dorr Arthritis Institute, Department of Orthopedics, Arthritis Institute at Centinela Hospital Medical Center, Inglewood, CA; and †Research Department, Orthopedic Hospital, Los Angeles, CA.*

Submitted October 30, 2004; accepted May 15, 2005.

Benefits or funds were received in partial or total support of the research material described in this article from the Sulzer Orthopaedics (Dr Campbell).

Reprint requests to: Lawrence D. Dorr, MD, Arthritis Institute, 501 E. Hardy Street, 3rd Floor, Los Angeles, CA 90031.

© 2006 Elsevier Inc. All rights reserved.

0883-5403/06/1906-0004\$32.00/0

doi:10.1016/j.arth.2005.05.026

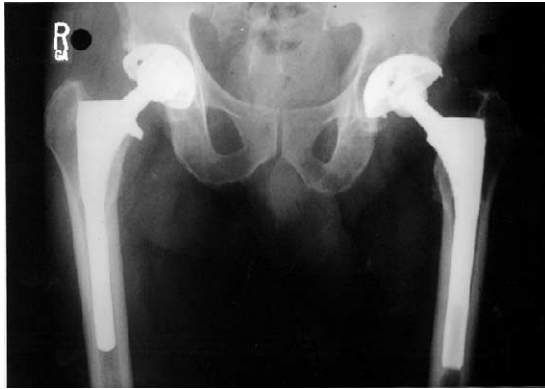

Fig. 1. Case 1. Anteroposterior pelvis radiograph with left hip revision 6 years postoperative and 1 year postoperative primary right total hip arthroplasty with a noncemented Anatomic Porous Replacement stem and noncemented Converge acetabular cup and a 28-mm Metasul head and liner.

implants to the bone as judged by the absence of radiolucent lines and no migration (Fig. 1). He had been evaluated by a pain management physician who administered 1 epidural injection, which gave relief for 24 hours. It was decided that his hip was the source of his symptoms. At 1 year postoperative, his symptoms and examination remained the same and he was unhappy with this hip arthroplasty. The possibility of a hypersensitivity reaction in his hip was discussed with him. His only known allergy was to codeine. A decision was made to change the Metasul articulation. At the revision surgery, the implants were well fixed and a ceramic

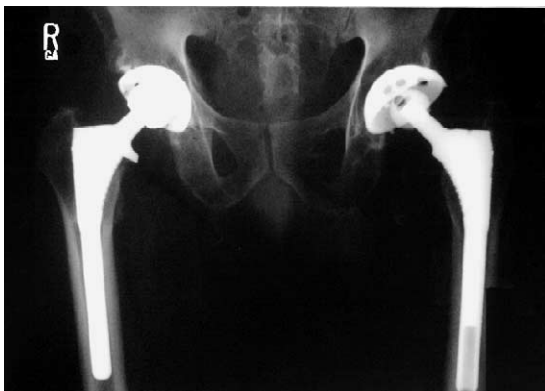

Fig. 2. Case 1. Anteroposterior pelvis radiograph 12 months postrevision of right hip, demonstrating 32-mm zirconium ceramic head mating with polyethylene acetabular insert. Intraoperatively, at the time of revision, both the femoral and acetabular components were tested and found to be well fixed.

head with a polyethylene insert was used to replace the metal-on-metal articulation (Fig. 2). The patient had an asymptomatic left hip arthroplasty with a titanium noncemented cup and stem, and a ceramic head on polyethylene articulation. The decision to use a ceramic head was made with the patient because of the desire to remove all cobalt and chromium metal ions from the articulation in the hip, although there is an increased risk for fracture of the ceramic head as used as a second head on the taper.

His preoperative blood tests were an erythrocyte sedimentation rate of 16 and a C-reactive protein that was negative. The results of intraoperative cultures were negative. The histology of tissues from posterior, deep posterior, medial, anterior, and superior capsules, as well as the acetabular membrane, was characterized by typical fibrous tissue with occasional macrophages containing dense micrometer-sized metallike particles. With the exception of some ulceration of the superior capsule surface, there were no unusual features in these specimens. By contrast, 1 piece of tissue from an unlabeled capsule site contained numerous focal perivascular lymphocytic aggregates infiltrated with plasma cells (Fig. 3). A sample of the patient's serum was taken before revision and was sent to Rush Presbyterian St Luke's Medical Center in Chicago, Ill, where a 7-day lymphocyte proliferation assay was performed [3], which revealed a moderate degree (6-fold) of lymphocyte hyperreactivity to nickel indicated by proliferation and flow cytometric assays of peripheral lymphocytes exposed to metals (Fig. 4). There was no increased reactivity to cobalt or chromium.

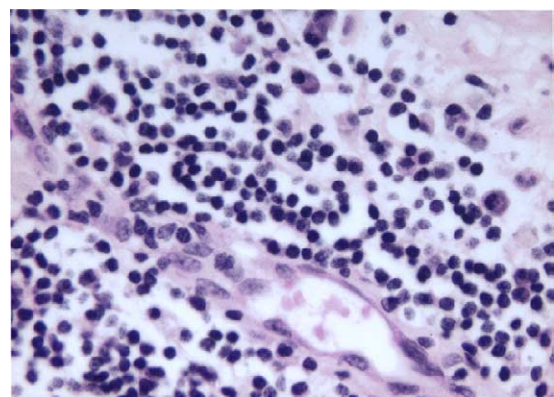


Fig. 3. Case 1. Capsule tissue photomicrograph demonstrating numerous perivascular lymphocytic aggregates infiltrated with plasma cells (hematoxylin-eosin, original magnification $\times 400$).

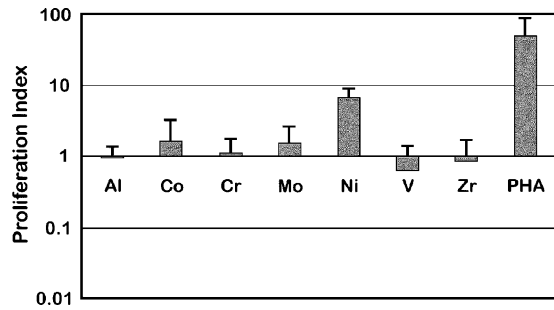


Fig. 4. Case 1. Seven-day lymphocytic proliferation assay demonstrating 6.1-fold proliferation to nickel over the control (moderate hyperreactivity). PHA indicates phytohemagglutinin (a lectin which activates lymphocytes as a positive control).

The clinical results of this revision surgery did not change the pain and function for this patient. At 1 year after revision, he still had groin pain and limp. He was diagnosed by an orthopedic spine specialist as having spinal stenosis and was treated with physical therapy and epidurals with intermittent relief, and a spine surgery was performed. One year after the spine surgery, he had relief of pain.

Case 2

A 54-year-old man with osteoarthritis of his left hip had a left total hip arthroplasty with a non-cemented Anatomic Porous Replacement stem and Converge cup with Metasul metal-on-metal artic-

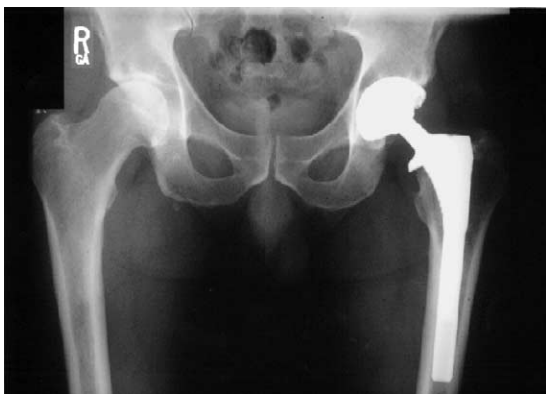

Fig. 5. Case 2. Two years–postoperative anteroposterior pelvis radiograph of left hip arthroplasty with a non-cemented Anatomic Porous Replacement stem and non-cemented Converge acetabular cup and a 28-mm Metasul head and liner. This prerevision anteroposterior pelvis x-ray demonstrates well-fixed femoral and acetabular components with no radiolucencies or osteolysis.

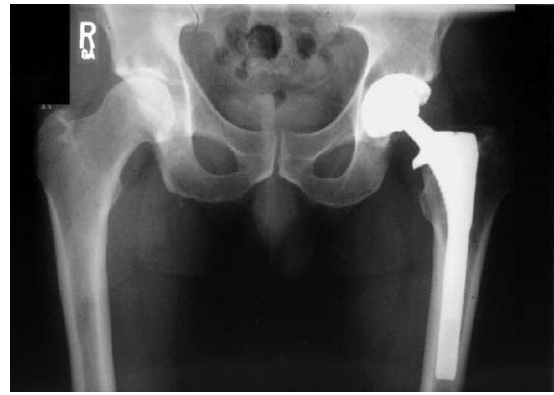

Fig. 6. Case 2. Six months–postrevision radiograph of left hip demonstrating 32-mm zirconium ceramic head mated with polyethylene acetabular insert. Intraoperatively, at the time of revision, both the femoral and acetabular components were tested and found to be well fixed. There are no radiolucencies or osteolysis in either the pelvis or acetabulum.

ulation. He also had osteoarthritis of his right knee with valgus deformity, which he believed was not of clinical importance to him. At 1 year after his operation, the patient felt that he was worse compared with his preoperative pain and function because he had anterior and lateral hip pain, thigh pain, and a limp. His x-rays showed his components to be in good position with evident fixation to bone as judged by no radiolucent lines and no migration (Fig. 5). He was evaluated by an orthopedic spine specialist who did not diagnose any significant spine disease and concluded that the pain was from his hip. At 2 years after the operation, he was still complaining of the left hip

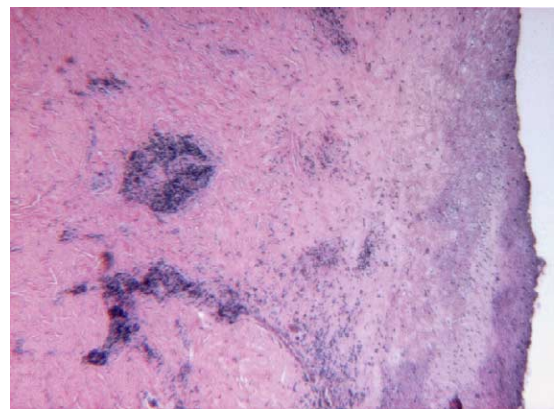


Fig. 7. Case 2. Typical histology from periprosthetic tissues showing fissured and partly necrotic synovial tissue with underlying perivascular lymphocytic aggregates (hematoxylin-eosin, original magnification $\times 40$).

pain and an inability to bear weight for prolonged periods of time on his left hip. On physical examination, he did have tenderness to palpation of his left posterior hip capsule. His right knee arthritis was also clinically disabling. The possibility of a hypersensitivity reaction to his metal-on-metal articulation had been discussed with him throughout the 2 year postoperative period, and he made a decision to have the articulation surface changed at the same time that he had a right total knee arthroplasty. His only known allergy was to monosodium glutamate. His preoperative blood tests were an erythrocyte sedimentation rate of 47 and a C-reactive protein that was negative.

At his revision operation, his implants were well fixed and he had the Metasul surfaces exchanged to a Durasul insert and zirconia ceramic femoral head (Centerpulse), understanding the increased fracture risk with using the ceramic head on this taper (Fig. 6). The goal was to remove all the cobalt and chromium metal ions from the articulation of the hip. Fluid obtained intraoperatively from his hip had a cell count of 1200 white blood cells with 39% polymorphonuclear cells and 61% mononuclear cells, and the cultures taken intraoperatively did not grow any bacteria. Light microscopic evaluation of the 5 periprosthetic tissues showed perivascular and diffuse lymphocytes, and plasma cells in each specimen. The synovial surface was often fissured and had a necrotic appearance in places (Fig. 7). Edema, bleeding, and deposits of hematin in macrophages were common findings. Metal-filled macrophages were rare. Serum that was obtained before the revision was examined by a 7-day proliferation assay that revealed mild reactivity (2.4-fold) to chromium (Fig. 8).

After his revision operation and removal of the cobalt chrome bearings, this patient did not become free of hip pain. At 1 year and 3 months

after his revision, the patient had intermittent periods where he had pain but his pain was much less. He did think that because his knee was getting progressively better, his hip was also getting progressively better. He did not have any more left thigh pain.

Discussion

We have performed 470 total hip arthroplasties with Metasul metal-on-metal articulation. There have been only 3 of these hips that have had pain of unexplained origin. Of the 3, 2 are the subject of this case report. It is possible that even in these hips, the source of pain has declared itself with more time. The patient in case 1 has been diagnosed with stenosis of the lumbar spine, and it is possible that this stenosis may be contributing to the hip pain; the hip in case 2 may have had increased pain because of the overload of that leg created by the contralateral arthritic knee. In neither patient was hypersensitivity to the metal-on-metal articulation a cause of the pain as shown by the postoperative revision clinical outcome.

The diagnosis of hypersensitivity to Metasul metal-on-metal articulations has only been an observation on pathology specimens [4]. There is no clinical record of hypersensitivity causing pain or failure of a hip arthroplasty recorded in literature. The pathology specimens from which this observation was made were those of failed hips and not autopsy retrieval specimens of well-functioning hips [1,4]. Studies of the reactions of tissue surrounding well-fixed and failed orthopedic implants of various metallic compositions show that failed implants have a higher incidence of metallic corrosion and histologic changes [1,5]. It is possible that the perivascular lymphocytic pathology observed in the failed hip arthroplasties was a response to the overload of debris within the tissues from failure of the hip arthroplasty. It may have no relationship at all to the tissue response to a well-functioning metal-on-metal hip arthroplasty.

Hallab et al [3,6] have described a new technique to evaluate patients with possible delayed hypersensitivity through the use of a triple assay technique of blood. The 3-assay technique analysis is done on blood specimens and includes (1) a proliferation assay of white blood cells; (2) a cytokine analysis using enzyme-linked immunosorbent assay; and (3) a migration

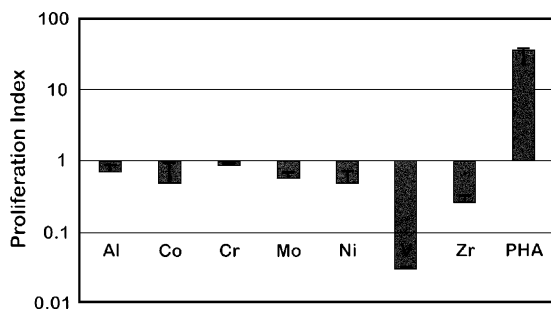


Fig. 8. Case 2. Seven-day lymphocytic proliferation assay demonstrating 2.4-fold proliferation to chromium over the control (mild hyperreactivity).

inhibition assay, which identifies a migration inhibitory factor, which was one of the first cytokines identified to be associated with delayed-type hypersensitivity reactions. When the results from all 3 assay tests are compared, metal-induced hypersensitivity can be quantified. In our patients, only the proliferation assay technique was used and this test did not strongly support sensitivity to cobalt or chrome as responsible for the clinical symptoms.

We still have no evidence of hypersensitivity to Metasul in our 470 hip arthroplasties with this articulation. In the future, because of the clinical course of these 2 patients after revision operation, we would not reoperate a patient with a painful hip arthroplasty with Metasul articulation for the diagnosis of hypersensitivity without positive laboratory evidence for this diagnosis. The best laboratory tests for us would be a strongly positive response to all 3 facets of the triple assay technique to both cobalt and chromium ions [3]. Otherwise, we will continue to observe patients with a painful Metasul hip arthroplasty to learn whether or not a clinical reason for the pain declares itself, as what seems to have happened in these 2 patients.

References

1. Willert HG, Buchhorn GH, Fayyazi A, et al. Histopathological changes in tissues surrounding metal/metal joints—signs of delayed type hypersensitivity? (DTH). In: Rieker C, Oberholzer S, editors. World Tribology Forum in Arthroplasty. Bern, Switzerland: Hans Huber; 2001. p. 147.
2. Willert HG, Buchhorn GH, Gobel D, et al. Wear behavior and histopathology of classic cemented metal on metal hip endoprostheses. *Clin Orthop* 1996; 329S:S160.
3. Hallab NJ, Mikecz K, Jacobs JJ. A triple assay technique for the evaluation of metal induced, delayed type hypersensitivity responses in patients with or receiving total joint arthroplasty. *J Biomed Mater Res* 2000;53:480.
4. Campbell P, Mirra J, Doorn P, et al. Histopathology of metal-on-metal hip joint tissues. In: Rieker C, Oberholzer S, editors. World Tribology Forum in Arthroplasty. Bern, Switzerland: Hans Huber; 2001. p. 167.
5. Sieber HP, Rieker CB, Kottig P. Analysis of 118 second-generation metal on metal retrieved hip implants. *J Bone Joint Surg Am* 1998;80B:46.
6. Hallab N, Merritt K, Jacobs JJ. Metal sensitivity in patients with orthopaedic implants. *J Bone Joint Surg Am* 2001;83A:428.